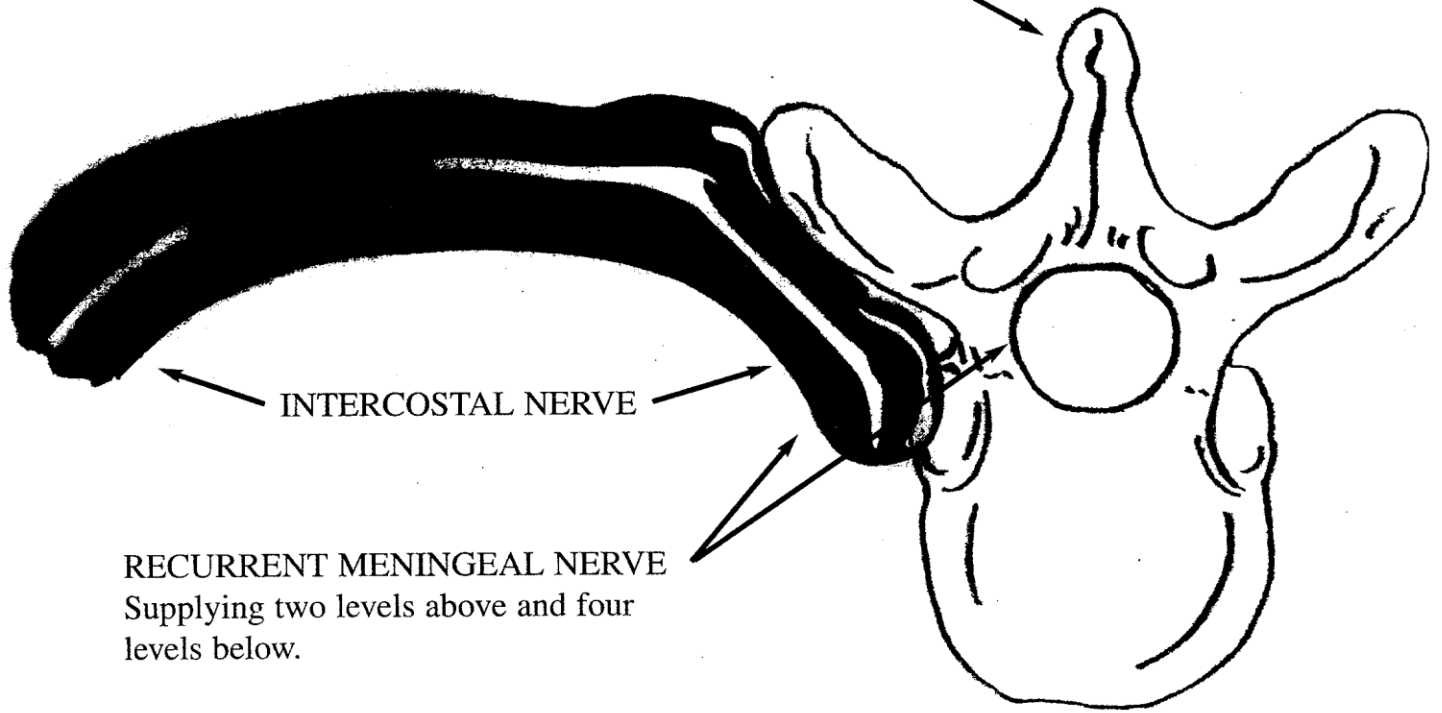
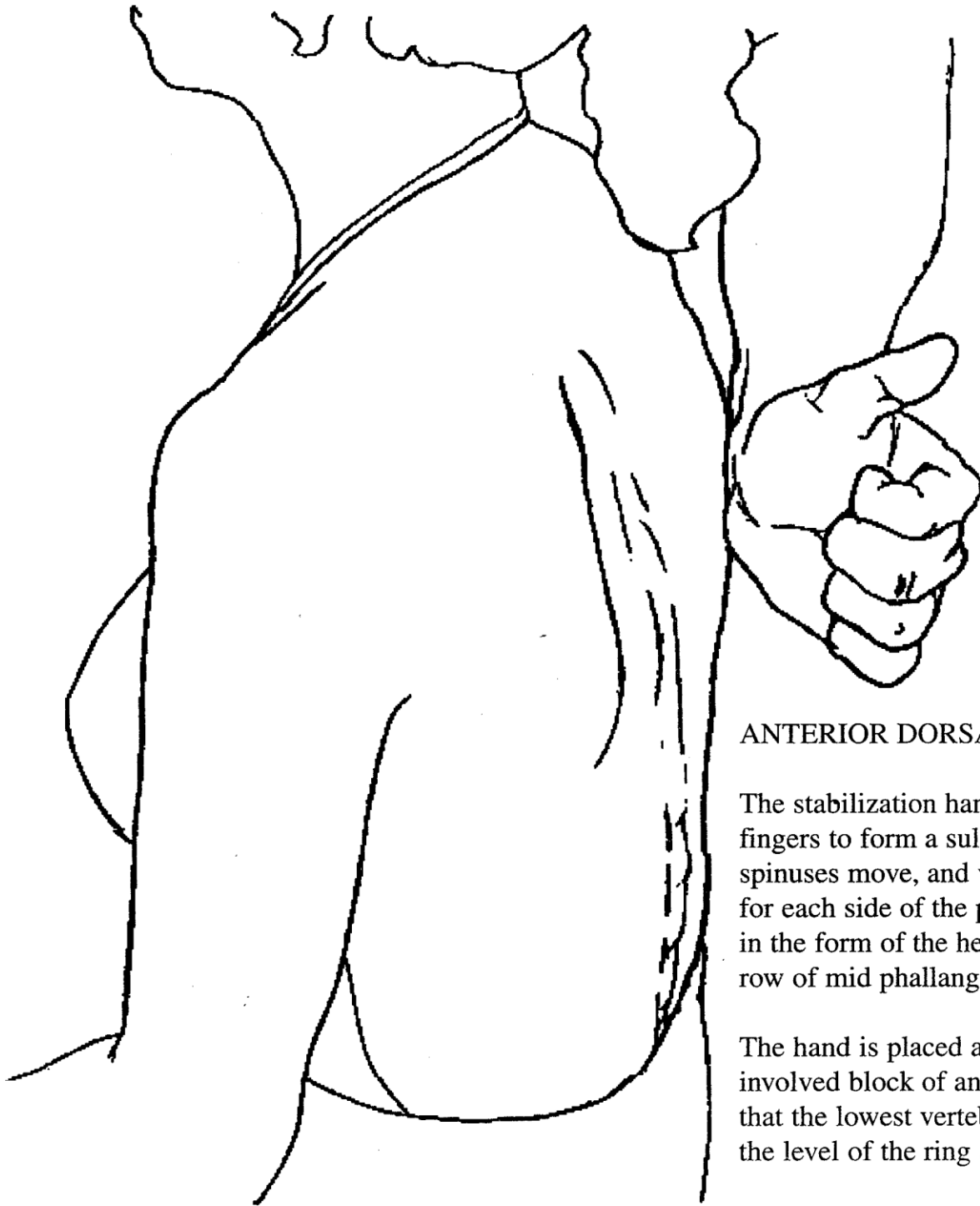


SINO-VERTEBRAL NERVE:  
Sensory nerve to the vertebra



INTERCOSTAL NERVE

RECURRENT MENINGEAL NERVE  
Supplying two levels above and four  
levels below.



#### ANTERIOR DORSALS T6-4

The stabilization hand curls the distal fingers to form a sulcu, into which the spinuses move, and vertical stabilizers for each side of the paraspinal muscles, in the form of the heel of the hand and a row of mid phallanges.

The hand is placed at the bottom of the involved block of anterior dorsals so that the lowest vertebra spinus (T6) is at the level of the ring and middle finger.

This placement can be adapted up or down the thoracic spine to the level of involvement and allows for tissue glide superior upon lying the patient down.